

Gunnar Heuser\* and Sylvia A. Heuser

# Functional brain MRI in patients complaining of electrohypersensitivity after long term exposure to electromagnetic fields

DOI 10.1515/reveh-2017-0014

Received April 3, 2017; accepted May 25, 2017; previously published online July 5, 2017

## Abstract

**Introduction:** Ten adult patients with electromagnetic hypersensitivity underwent functional magnetic resonance imaging (fMRI) brain scans. All scans were abnormal with abnormalities which were consistent and similar. It is proposed that fMRI brain scans be used as a diagnostic aid for determining whether or not a patient has electromagnetic hypersensitivity. Over the years we have seen an increasing number of patients who had developed multi system complaints after long term repeated exposure to electromagnetic fields (EMFs). These complaints included headaches, intermittent cognitive and memory problems, intermittent disorientation, and also sensitivity to EMF exposure. Regular laboratory tests were within normal limits in these patients. The patients refused to be exposed to radioactivity. This of course ruled out positron emission tomography (PET) and single-photon emission computed tomography (SPECT) brain scanning. This is why we ordered fMRI brain scans on these patients. We hoped that we could document objective abnormalities in these patients who had often been labeled as psychiatric cases.

**Materials and methods:** Ten patients first underwent a regular magnetic resonance imaging (MRI) brain scan, using a 3 Tesla Siemens Verio MRI open system. A functional MRI study was then performed in the resting state using the following sequences:

1. A three-dimensional, T1-weighted, gradient-echo (MPRAGE)
2. Resting state network. The echo-planar imaging (EPI) sequences for this resting state blood oxygenation level

dependent (BOLD) scan were then post processed on a 3D workstation and the independent component analysis was performed separating out the various networks.

3. Arterial spin labeling.
4. Tractography and fractional anisotropy.

**Results:** All ten patients had abnormal functional MRI brain scans. The abnormality was often described as hyper connectivity of the anterior component of the default mode in the medial orbitofrontal area. Other abnormalities were usually found. Regular MRI studies of the brain were mostly unremarkable in these patients.

**Conclusion:** We propose that functional MRI studies should become a diagnostic aid when evaluating a patient who claims electrohypersensitivity (EHS) and has otherwise normal studies. Interestingly, the differential diagnosis for the abnormalities seen on the fMRI includes head injury. It turns out that many of our patients indeed had a history of head injury which was then followed sometime later by the development of EHS. Many of our patients also had a history of exposure to potentially neurotoxic chemicals, especially mold. Head injury and neurotoxic chemical exposure may make a patient more vulnerable to develop EHS.

**Keywords:** electrohypersensitivity (EHS); electromagnetic field (EMF); fMRI; multiple chemical sensitivity (MCS).

## Introduction

In the past the senior author (G.H.) practiced clinical toxicology and in that capacity saw more than 1000 patients who had suffered exposure to toxic chemicals. Their impairment was often neurologic with loss of memory function, headaches, intermittent confusion, problems with balance, and other symptoms. This impairment had persisted, at times for years after exposure to these toxic chemicals had ceased. Some of these patients had developed sensitivity to even small amounts of chemicals resulting in multiple chemical sensitivity (MCS). More than 60 patients were eventually studied and the results were published in a peer reviewed journal [1]. All of these patients had single-photon emission computed tomography

\*Corresponding author: Gunnar Heuser, MD, PhD, Formerly UCLA Medical Center, Department of Medicine, PO Box 5066, El Dorado Hills, Los Angeles, CA 95762, USA, Phone: +(310) 500-0041, E-mail: toxguns@netscape.net, Website: emfdoc.com; Emeritus Cedars Sinai Medical Center, Department of Medicine, Los Angeles, CA, USA; Former Member of Brain Research Institute, UCLA Medical Center, Los Angeles, CA, USA  
Sylvia A. Heuser: Environmental, Medical, Research and Information Center (EMRIC), Santa Barbara, CA, USA

(SPECT) brain scans all of which were abnormal. Additional studies were then performed and published [2, 3].

More recently we began to see patients who reported significant reactions to even small amounts of electromagnetic fields (EMFs). Some of these patients had in the past been seen for problems with chemical exposure and had now developed electrohypersensitivity (EHS). Some of these patients also gave a history of head injury.

Electrohypersensitivity has since been acknowledged by the medical profession since it demands more and more attention and evaluation [4–7]. The syndrome has now been called EHS.

Patients with EHS develop multi-system complaints on exposure to currents emitted by cell phones, cell phone towers, smart meters, power-lines and other sources of EMFs.

In this paper we present patients with EHS who had undergone functional brain MRI studies because of their complaints which were mostly neurological after exposure: memory and cognitive impairment, attention deficit disorder, changes in behavior, and other symptoms. They presented with a history of long term exposure to EMFs followed by development of EHS.

Every patient included in this paper reported significant symptomatology which served to arrive at a diagnosis of EHS. Symptoms developed upon exposure and usually diminished or disappeared when removed from EMF source. Multi-symptoms included headaches, impairment of cognitive function, tremors, weakness, and others. Multi-system complaints were triggered by exposure to cell phones, cell phone towers, smart meters, wi-fi, and other sources (see description of individual cases).

A careful and thorough lab evaluation ruled out diseases which often cause multi system complaints e.g. thyroid problems, diabetes, autoimmune disease, chronic infections and other conditions. Patients often provided pictures of nearby cell phone towers, smart meters and other sources of EMFs to document their claim.

## Methodology

All patients signed a release form allowing us to publish the results of their study. Our control population consisted of 60 volunteers of both sexes, ages 15–70. They were not on drugs, had no known diseases and were otherwise in perfect health. Our study group consisted of 10 patients all of whom experienced long term EMF exposure and developed EHS.

All patients had regular magnetic resonance imaging (MRI) brain scans using a 3 Tesla Siemens Verio MRI Open system. This was followed by an fMRI study, using the following sequences:

1. A three-dimensional, T1-weighted, gradient-echo (MPRAGE).
2. Resting state network. The echo-planar imaging (EPI) sequences for this resting state blood oxygenation level dependent (BOLD)

**Table 1:** Patient population.

Case number	Age	Gender	Head injury	Chem. Ex.
Case #1	60's	Female	Yes	Yes
Case#2	40's	Male	No	No
Case #3	60's	Male	Yes	Yes
Case #4	50's	Female	No	Yes
Case #5	50's	Female	No	Yes
Case #6	60's	Female	No	Yes
Case #7	70's	Male	No	Yes
Case #8	60's	Female	Yes	Yes
Case #9	60's	Female	Yes	Yes
Case #10	60's	Male	Yes	Yes

scan were then post processed on a 3D workstation and the independent component analysis was performed separating out the various networks.

3. Arterial spin labeling.
4. Tractography and fractional anisotropy (Table 1).

## Results

**Case 1.** This right handed patient was in her early sixties when she was evaluated. Whenever exposed to EMFs she developed cognitive and memory problems as well as a sense of malaise to the point of inability to function. Her EHS developed over the years. Her history includes multiple head injuries and also exposure to toxic chemicals, including mold, eventually resulting in multiple chemical sensitivity (MCS)

The fMRI showed severely abnormal default mode network (DMN) with hyper connectivity of the anterior component in the medial orbitofrontal area, also decrease of white matter tracts within the right frontal lobe, and finally decreased flow and/or metabolism within bifrontal lobes (Figure 1).

**Case 2.** This right handed patient was in his forties when evaluated. Several years before he had an abnormal SPECT brain scan and an abnormal neuropsychological test result suggesting attention deficit disorder (ADD). For approximately 11 years he had worked as an air conditioning expert, working on the roofs of many commercial buildings, thus being exposed to EMFs. He developed cognitive and memory problems, impaired coordination and balance, insomnia, chronic fatigue, and finally EHS. In addition he was diagnosed to have bi-lateral cataracts impairing his vision. His history is negative for head injury and toxic chemical exposure.

The fMRI showed abnormality of the DMN with increased hyperconnectivity of the anterior component.

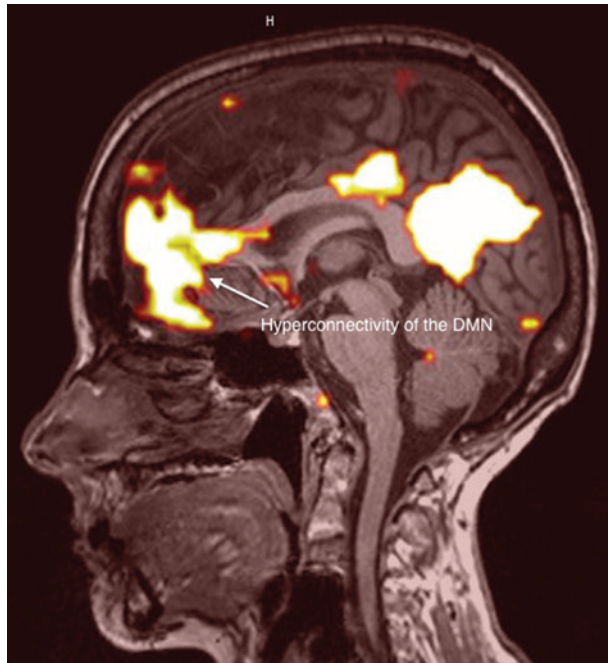


Figure 1: Lateral view of case no. 1.

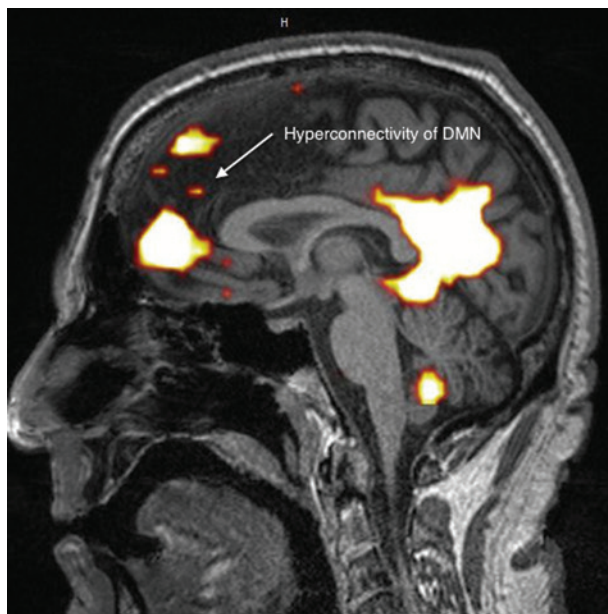


Figure 2: Lateral view of case no. 2.

Fractional anisotropy was found to be decreased in the corpus callosum (Figure 2).

**Case 3.** This right handed patient was in his sixties when being evaluated. He had worked in a high voltage environment as a journeyman lineman for more than 30 years, evaluating and treating problems in that environment.

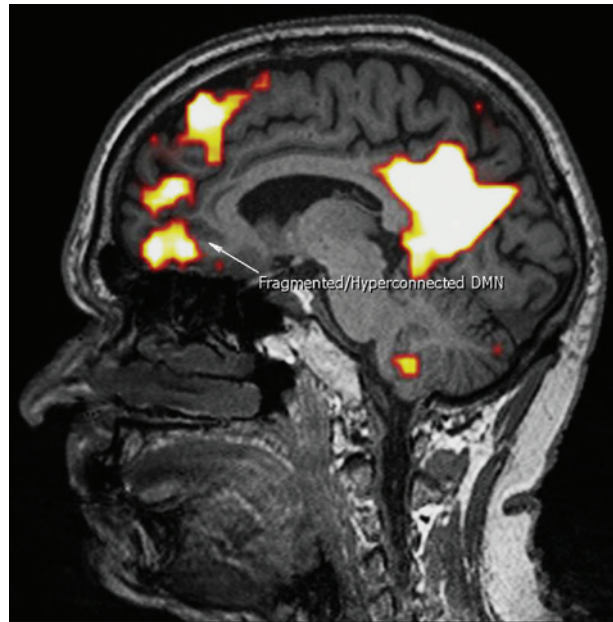

Figure 3: Lateral view of case no. 3.

Eventually, he developed a seizure disorder with loss of consciousness. His seizures subsided when he was off work and returned when he returned to work.

He had a concussion in his teenage years. He had not been exposed to mold.

The fMRI showed fragmentation of the anterior component of the DMN, also decreased fractional anisotropy, predominantly in the corpus callosum (Figure 3).

**Case 4.** This right handed patient was in her early fifties when tested. Exposure to chemicals started in childhood when she developed double pneumonia, allergies, and eventually asthma

For years before our testing she worked as an air traffic controller, surrounded by cell phone towers at work. In that setting she developed EHS.

Her history is negative for head injury. Her past history includes exposure to mold.

The fMRI showed abnormal DMN with hyper connectivity and fragmentation of the anterior component. There was also hyper connectivity of the posterior component. Finally there was decreased flow and/or metabolism in the bifrontal lobes (Figure 4).

**Case 5.** This left handed female was in her early fifties when tested. About 15 years earlier she was exposed to chemicals and eventually developed MCS. About 9 years earlier she got into the habit of holding her cell phone to her left ear in which she eventually developed pain, whenever she was using the phone. Additional symptoms



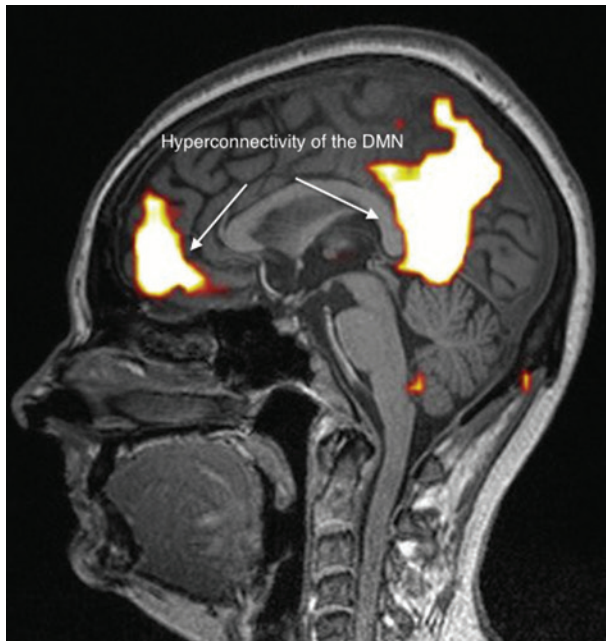


Figure 4: Lateral view of case no. 4.

eventually developed and included impaired cognitive function, intermittent confusion, headaches, nausea, and generalized weakness, all of these eventually developing into EHS. Her history is negative for head injury and for mold exposure.

The fMRI showed markedly hyperconnected medial orbitofrontal component in the resting state network. Diminished marked asymmetry of blood flow with

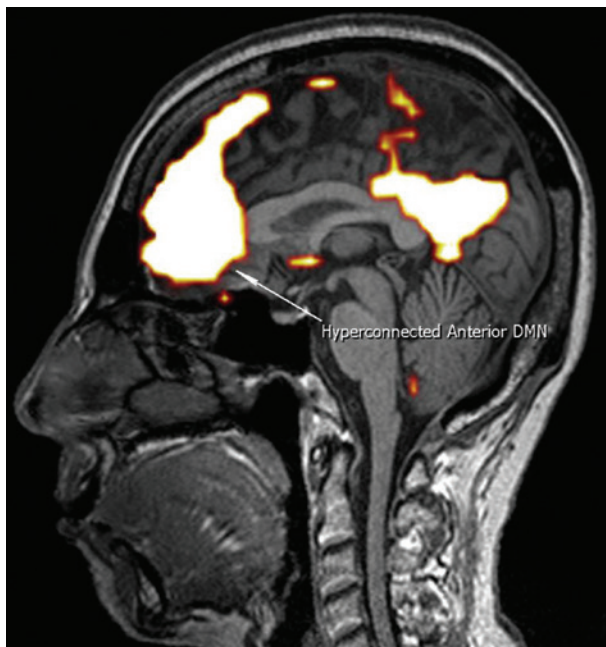

Figure 5: Lateral view of case no. 5.

diminished flow in the right frontal temporal region was also found (Figure 5).

**Case 6.** This left handed patient was in her sixties when evaluated. Just a few years before, AT&T constructed a cell phone tower about 500 yards from her home. She developed impaired memory, speech pressure, insomnia, dry eyes and eventually EHS.

Her history is negative for head injury and positive for mold exposure.

The fMRI showed severely abnormal DMN with hyperconnectivity of the anterior component (Figure 6).

**Case 7.** This right handed male was in his seventies when tested. In his work area he had been exposed to EMFs, being surrounded by cell phone towers, many computers, and electrical equipment. He had developed memory and cognitive problems, together with headaches and eventually EHS. Years ago he had been exposed to diesel fumes and more recently to mold. The history is negative for head injury.

The fMRI showed abnormal DMN with fragmentation of the anterior component in the medial orbitofrontal area. It also showed decreased flow and/or metabolism within the bilateral posterior parietal lobes. Finally diffusely decreased white matter tracts in the left cerebral hemisphere were found (Figure 7).

**Case 8.** This right handed patient was in her sixties when testing was done. EMF exposure started around 2005 and

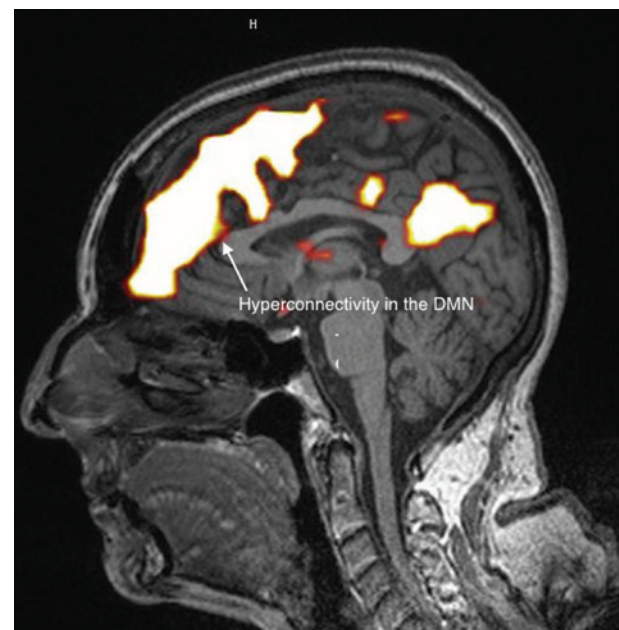

Figure 6: Lateral view of case no. 6.

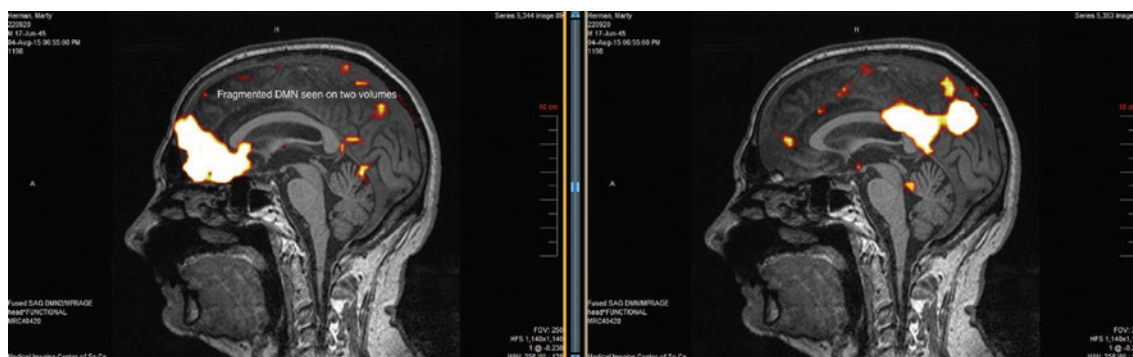


Figure 7: Lateral views of case no. 7.

continued ever since. This continual exposure eventually resulted in the development of EHS. Her complaints included headaches, insomnia, blurred vision, and impairment of speech. Her medical history includes allergies including asthma, mold exposure, and head injuries at ages 10 and 21.

The fMRI showed abnormal DMN with hyper connectivity of the anterior component of the medial orbitofrontal area. Also found was mildly decreased flow and/or metabolism in the bifrontal lobes (arterial spin labeling). Finally there was symmetric loss of white matter tracts in the left posterior parietal lobe (Figure 8).

**Case 9.** This right handed patient was in her early sixties when evaluated. For more than 20 years she had tested

and repaired batteries and was therefore exposed to toxic metals and EMFs on every working day. She was also exposed to a nearby cell phone tower at work.

She developed cognitive and memory impairment, numbness, and eventually EHS and a seizure disorder. Additional medical history included an industrial accident with “electrocution” and also exposure to mold, first at work then at home. Finally her history is positive for head injury.

The fMRI showed a hyperconnected anterior component of the DMN in the medial orbitofrontal area. Also found was decreased fractional anisotropy in the body of the corpus callosum. Finally there was diminished flow within the bifrontal lobes (Figure 9).

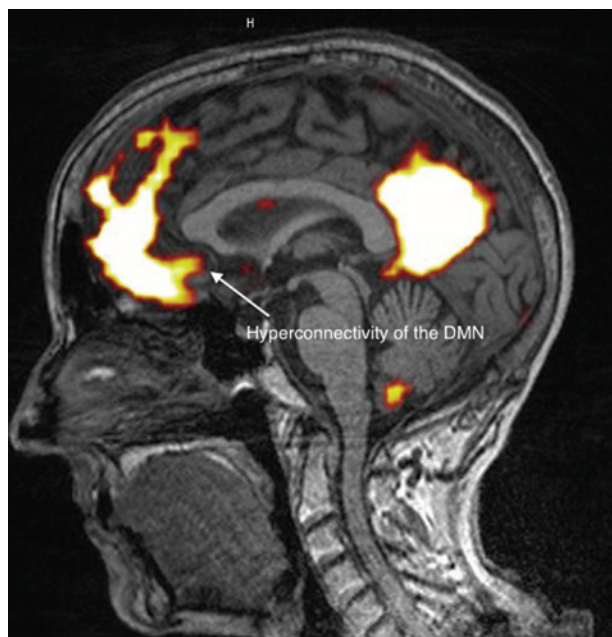


Figure 8: Lateral view of case no. 8.

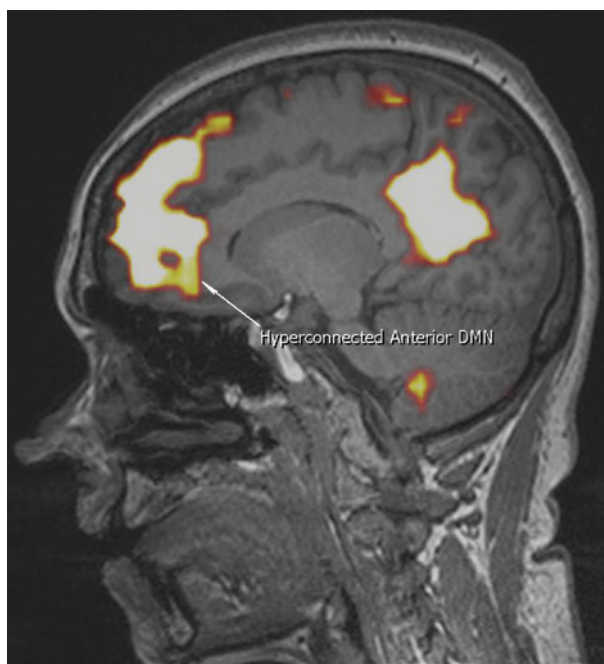


Figure 9: Lateral view of case no. 9. (A) Sample MRI report for case no. 9. (B) Sample fMRI report for case no. 9.

**A****MRI OF THE BRAIN****HISTORY****Name: DOB:** 12/28/1954 Female**Exam Date:** 9/8/14**Referring Phys.:** GunnarHeuser,M.D.

This is a 59-year-old female with exposure to mold and mercury. The patient has symptoms of seizures, memory loss, and numbness in hands and left arm.

**PROCEDURE**

Using a 3 Tesla Siemens Verio MRI Open system, the following sequences were obtained:

- |                           |                                     |
|---------------------------|-------------------------------------|
| 1) Localizer.             | 4) DWI axial.                       |
| 2) T1 3D sagittal MPRAGE. | 5) SWI axial.                       |
| 3) T2 FLAIR sagittal.     | 6) T2 FLAIR axial. 7) T2 TSE axial. |

**FINDINGS**

No cavum septum pellucidum is seen. No blood products are visualized. There is no diffusion restriction.

There is no focal or global volume loss.

The posterior fossa is normal.

The sella and parasellar regions are normal. The flow voids of the vessels of the skull base are identified and normal.

The mastoid air cells, paranasal sinuses, and orbits are normal.

There are scattered foci of T2/FLAIR hyperintensity within the supratentorial subcortical white matter located in bifrontal lobes.

**IMPRESSION**

Scattered foci of T2/FLAIR hyperintensity in the supratentorial subcortical white matter representing gliosis. This can be seen in the setting of prior head trauma, chronic migraine headaches, less likely chronic small vessel ischemic disease given distribution.

**B****FUNCTIONAL MRI (fMRI) OF THE BRAIN****HISTORY DOB:** 12/28/1954 Female**Exam Date:** 9/8/14**Referring Phys.:** GunnarHeuser, M.D.

This is a 59-year-old female with exposure to mold and mercury, has symptoms of blackout, seizure, memory loss, head trauma to the left side of brain.

**PROCEDURE**

Using a 3 Tesla Siemens Verio MRI Open bore system, a functional MRI study was performed using the followings equences:

- 1) MPRAGE.
- 2) Resting state network. The EPI sequences for this resting state BOLD scan were then post processed on a 3D workstation and the independent component analysis performed separating out the various networks.
- 3) Arterial spin labeling.
- 4) Tractography and fractional anisotropy.

**FINDINGS**

There is a markedly abnormal default mode network with hyperconnectivity of the anterior component of the default mode. This can be seen in the setting of OCD, chronicpain, post-traumatic brain injury and/or drug abuse.

The fractional anisotropy is low within the body of the corpus callosum with a minimal value of 0.22 in the anterior body .Diffusion tensor imaging is within normal.

The arterial spin labeling demonstrates symmetric diminished flow within bifrontal lobes.

**IMPRESSION**

1. Abnormal functional MRI with hyperconnected anterior component of the default mode network in the medial orbitofrontal area. This can be seen in the setting of traumatic brain injury, chronic pain, substance abuse and/or OCD.
2. Decreased fractional anisotropy within the body of the corpus callosum with a minimal value of 0.22 in the anterior body. This is a sign of disorganization of fibers which can be seen in the setting of traumatic brain injury.
3. There is diminished flow within bifrontal regions which is consistent with hypometabolic activity. This can be seen in the setting of traumatic brain injury.

**Figure 9 (continued)**

**Case 10.** This right handed patient was in his sixties when testing was done. Over the years he had been exposed to pesticides and to mold. He had experienced a concussion about 10 years earlier. He gradually developed EHS.

The fMRI showed abnormal DMN with fragmentation and hyper connectivity of the anterior component of the default mode in the medial orbitofrontal area. There was borderline decreased flow and/or metabolism within bifrontal lobes (Figure 10).



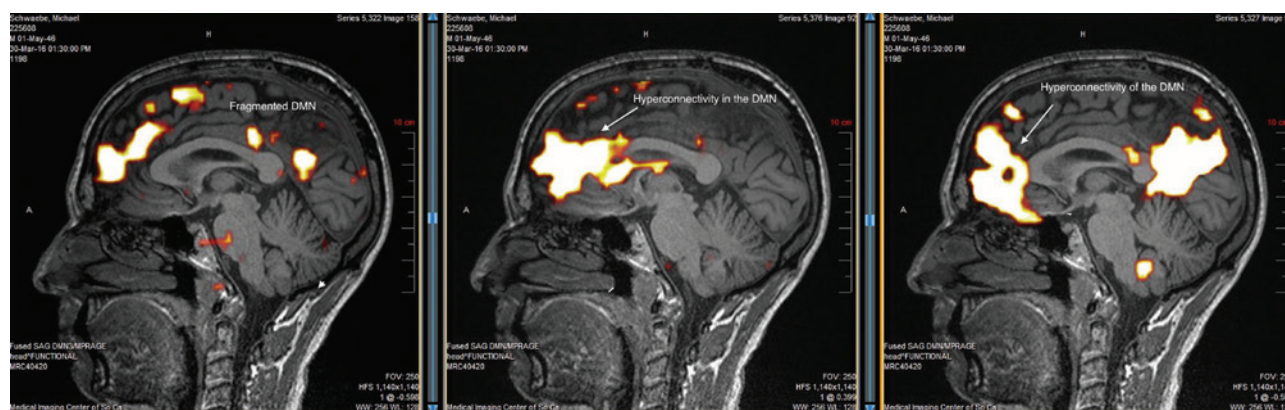


Figure 10: Lateral views of case no. 10.

## Discussion

More than 30 years ago we became interested in the effects of toxic chemical exposure on the brain. We selected more than 70 patients who had developed multi system complaints after long-term exposure to potentially neurotoxic chemicals. All patients underwent functional brain scans of the SPECT type. They were all abnormal and statistically analyzed. The results were published [1] in a peer reviewed journal with the conclusion that neurotoxic chemical exposure can lead to long-term effects including abnormalities in brain function. The abnormalities seen were still present years after toxic exposure had ceased. The potentially neurotoxic effects of chemicals were further discussed in a German publication [3].

Since some of our patients had developed exquisite sensitivity to even small amounts of chemicals we decided to document brain function in these patients with multiple chemical sensitivity (MCS). For this study we chose positron emission tomography (PET) scanning of the brain and found definite objective abnormalities in these patients. The results were published with the conclusion that patients with MCS have objective abnormalities in brain function [2]. It should be noted that a number of PET studies were published by other authors but did not address MCS [4–7].

Of interest was the fact that PET brain scans in MCS patients showed increased activity in the amygdala [2]. This structure is known to control emotions. This is why some patients with MCS develop an emotional disorder which can be explained on the basis of a “hot” amygdala. In view of this past finding with our MCS patients we believe that EHS patients should be studied with PET scans so as to find out whether their amygdalae are also hyperactive.

MCS was further discussed in a consensus paper in which GH was a co-author [8].

In more recent years we started seeing patients who claimed exquisite sensitivity to electromagnetic fields (electrohypersensitivity, commonly recognized as EHS). It was very interesting to find that the complaints these patients had developed were similar to the complaints patients had who were exposed to and sensitive to chemicals: headaches, cognitive and memory problems, intermittent problems with balance, and intermittent tremor. This syndrome has been described by Carpenter and others [9–12].

The late Dr. Ross Adey [13] found that chemicals and EMFs can interact and aggravate each others’ effects. This became a finding we confirmed in our patients.

We suggested to some of our patients with EHS that they undergo a functional brain scan to document potential abnormalities. They agreed but did not want to have any radioactive material used for the scan. This of course excluded PET and SPECT scanning of the brain. Since these patients had significant complaints and were at times disabled we felt that it was important to obtain a functional MRI (fMRI) to document potential abnormalities of brain function. In the beginning this was considered as medically necessary and was not a research project and therefore not funded by any agency. Since insurance coverage is not yet available for fMRI, patients had to cover the cost of the whole evaluation. While fMRI studies look at functional connections between some brain areas, no studies in the literature specifically addressed functional connectivity after exposure to EMF. However, some studies in the literature refer to connections between specific areas of the brain by measuring EEG and related activities. None of these studies have addressed patients with EHS [14–16].

## Conclusion

All fMRI brain scans were abnormal in our patients. Their abnormalities were very similar in all of them.

The study of fMRI created a new language which had to be learned. We have included some references which help the reader to understand this new terminology [17–21].

The question now arises whether the same abnormalities seen in all 10 patients can become a diagnostic aid or biomarker for determining whether or not a patient has electrohypersensitivity (EHS). Some researchers have claimed that a diagnosis of EHS should really be a psychiatric diagnosis [22]. Other researchers have attempted to measure EHS [23]. The possible psychiatric aspects of EHS remind us of the history of medicine when epilepsy was considered to be a diagnosis of possession by the devil [24]. It was only the discovery of the EEG which helped to find epilepsy to be a real disease with objective findings. We hope that fMRI will play the role of the EEG in EHS.

In the context of the above paragraph we should mention the articles by Belpomme et al. [25] and De Luca et al. [26] which suggest a long list of biomarkers for the diagnosis of EHS. This list does not include functional brain scans as potential biomarkers.

The treatment of EHS is very difficult. It was reviewed in a recent publication [27]. We have found that hyperbaric oxygen is at times helpful [28]. We have proposed that every patient with EHS should be checked for mast cell disease since mast cell abnormalities were found by Gangi and Johansson [29]. We described mast cell disorder in patients with MCS [30]. Also we found mast cell disorder in some of our patients with EHS [31]. Finally we believe that mold and mold toxin (mycotoxin) exposure can trigger EHS. Mast cell disease and mold problems are treatable. Their treatment may decrease EHS. Otherwise treatment consists basically of avoidance.

A final point of interest is the fact that the abnormality seen on the fMRI can also be seen after head injury [32, 33]. Indeed, many of our patients complaining of EHS have a history of head injury (see our case reports).

Since neurotoxic chemicals as well as head injury and EMF exposure are known to impair the blood brain barrier, it is almost to be expected that singly or in combination they make a given patient more vulnerable to impaired brain function (including seizures).

In the past we studied patients who had developed multi system complaints after exposure to a number of neurotoxins. The only patients who developed a seizure disorder were the ones who gave a history of past head injury [31]. Two of our patients (#3 and 9) developed a well

documented seizure disorder. This can be understood as having been “kindled” by repeated exposures to EMFs.

Our study needs to be enlarged and also duplicated by others. The subject will be of increasing importance in our society in which we and our children are all exposed to more and more EMFs.

**Acknowledgements:** Medical Imaging of Southern California graciously made their studies (MRI and fMRI) available at a significant discount. We also acknowledge Brea Blevins who helped to retrieve and to display the images published in this paper. Most patients were either self referred or referred by their physician. Some were referred by The Peoples Initiative Foundation which was formed and is directed by Elizabeth Barris.

### Author Statement

**Research funding:** No funds for this study were available from any foundation or other financial entity for this study. **Partial payment** was received for two patient studies by a charitable foundation (The Peoples Initiative Foundation). Patients paid for their own consultations and testing. **No insurance reimbursements** were available for the fMRI study. **Conflict of interest:** Authors state no conflict of interest. **Informed consent:** Informed consent has been obtained from all individuals. **Ethical approval:** Ethical approval was not applicable.

## References

1. Heuser G, Mena I. Neurospect in neurotoxic chemical exposure. Demonstration of long-term functional abnormalities. *Toxicol Ind Health* 1998;14(6):813–27.
2. Heuser G, Wu JC. Deep subcortical (including limbic) hypermetabolism in patients with chemical intolerance: human PET studies. *Ann N Y Acad Sci* 2001;933:319–22.
3. Heuser G. Functional brain Imaging with SPECT and PET after neurotoxic exposure: two and three-dimensional displays. *Zeitschrift für Umweltmedizin* 1999;8:284–5.
4. Huber R, Treyer V, Schuderer J, Berthold T, Buck A, et al. [Exposure to pulse-modulated radio frequency electromagnetic fields affects regional cerebral blood flow.](#) *Eur J Neurosci* 2005;21(4):1000–6.
5. Aalto S, Haarala C, Brück A, Sipilä H, Hämäläinen H, et al. Mobile phone affects cerebral blood flow in humans. *J Cereb Blood Flow Metab* 2006;26(7):885–90.
6. Haarala C, Aalto S, Hautzel H, Julkunen L, Rinne JO, et al. Effects of a 902 MHz mobile phone on cerebral blood flow in humans: a PET study. *Neuroreport*. 2003;14(16):2019–23.
7. Huber R, Treyer V, Borbély AA, Schuderer J, Gottselig JM, et al. Electromagnetic fields, such as those from mobile phones, alter regional cerebral blood flow and sleep and waking EEG. *J Sleep Res* 2002;11(4):289–95.



8. Bartha L. Multiple chemical sensitivity: a 1999 consensus. *Arch Environ Health* 1999;54(3):147–9.
9. Carpenter DO. The microwave syndrome or electrohypersensitivity: historical background. *Rev Environ Health* 2015;30(4):217–22.
10. Hedendahl L, Carlberg M, Hardell L. Electromagnetic hypersensitivity – an increasing challenge to the medical profession. *Rev Environ Health* 2015;30(4):209–15.
11. Genuis SJ, Lipp CT. [Electromagnetic hypersensitivity: fact or fiction? Sci Total Environ](#) 2012;414:103–12.
12. McCarty DE, Carrubba S, Chesson AL, Frilot C, Gonzalez-Toledo E, et al. Electromagnetic hypersensitivity: evidence for a novel neurological syndrome. *Int J Neurosci* 2011;121(12):670–6.
13. Adey WR. [Joint actions of environmental nonionizing electromagnetic fields and chemical pollution in cancer promotion. Environ Health Perspect](#) 1990;86:297–305.
14. Haarala C, Takio F, Rintee T, Laine M, Koivisto M, et al. Pulsed and continuous wave mobile phone exposure over left versus right hemisphere: effects on human cognitive function. *Bioelectromagnetics* 2007;28(4):289–95.
15. Vecchio F, Babiloni C, Ferreri F, Curcio G, Fini R, et al. [Mobile phone emission modulates interhemispheric functional coupling of EEG alpha rhythms. Eur J Neurosci](#) 2007;25(6):1908–13.
16. Yang L, Chen Q, Lv B, Wu T. [Long-Term evolution electromagnetic fields exposure modulates the resting state EEG on alpha and beta bands. Clin EEG Neurosci](#) 2017;48(3):168–75.
17. van den Heuvel MP, Hulshoff Pol HE. Exploring the brain network: a review on resting-state fMRI functional connectivity. *Eur Neuropsychopharmacol* 2010;20(8):519–34.
18. Horn A, Dirk O, Reiser M, Blankenburg F. Default Mode Network. [revised 2016 August]. In: Wikipedia [Internet]. San Francisco, CA: Neurolmage; 2006 September. 10 pages. Available from: [www.wikipedia.com](http://www.wikipedia.com). DOI: 10.1016.
19. Liston C, Chen AC, Zebley BD, Drysdale AT, Gordon R, et al. [Default mode network mechanisms of transcranial magnetic stimulation in depression. Biol Psychiatry](#) 2014;76(7):517–26.
20. Smith SM, Vidaurre D, Beckmann CF, Glasser MF, Jenkinson M, et al. Functional connectomics from resting-state fMRI. *Trends Cogn Sci* 2013;17(12):666–82.
21. Lee MH, Smyser CD, Shimony JS. [Resting-state fMRI: a review of methods and clinical applications. AJNR Am J Neuroradiol](#) 2013;34(10):1866–72.
22. Rubin GJ, Hillert L, Nieto-Hernandez R, van Rongen E, Oftedal G. [Do people with idiopathic environmental intolerance attributed to electromagnetic fields display physiological effects when exposed to electromagnetic fields? A systematic review of provocation studies. Bioelectromagnetics](#) 2011;32(8):593–609.
23. Tuengler A, von Klitzing L. Hypothesis on how to measure electromagnetic hypersensitivity. *Electromagn Biol Med* 2013;32(3):281–90.
24. Espí Forcén C, Espí Forcén F. Demonic possessions and mental illness: discussion of selected cases in late medieval hagiographical literature. *Early Sci Med* 2014;19(3):258–79.
25. Belpomme D, Campagnac C, Irigaray P. [Reliable disease biomarkers characterizing and identifying electrohypersensitivity and multiple chemical sensitivity as two etiopathogenic aspects of a unique pathological disorder. Rev Environ Health](#) 2015;30(4):251–71.
26. De Luca C, Chung Sheun Thai J, Raskovic D, Cesario E, Caccamo D, et al. Metabolic and genetic screening of electromagnetic hypersensitive subjects as a feasible tool for diagnostics and intervention. *Mediators Inflamm* 2014;2014:924184.
27. Rubin GJ, Das Munshi J, Wessely S. A systematic review of treatments for electromagnetic hypersensitivity. *Psychother Psychosom* 2006;75(1):12–8.
28. Heuser G, Uszler JM. Hyperbaric oxygenation for cerebral palsy. *Lancet* 2001;357(9273):2053–4. Erratum in: *Lancet* 2001 Nov 24;358(9295):1820.
29. Gangi S, Johansson O. A theoretical model based upon mast cells and histamine to explain the recently proclaimed sensitivity to electric and/or magnetic fields in humans. *Med Hypotheses* 2000;54(4):663–71.
30. Heuser G. Mast cell disorder to be ruled out in MCS. *Arch Environ Health* 2000;55(4):284–5.
31. Unpublished observations by authors.
32. Mishra AM, Bai X, Sanganahalli BG, Waxman SG, Shatillo O, et al. Decreased resting functional connectivity after traumatic brain injury in the rat. *Plos One* 2014;09(4):e95280.
33. Zhou Y, Milham M, Lui Y, Zhou Y, Milham MP, et al. Default-mode network disruption in mild traumatic brain injury. *Radiology* 2012;265(3):882–92.